



## Detecting Caries Around Amalgam Restorations With The Canary System®

### Introduction

One of our many challenges in dentistry is to answer the question: "When does that old restoration need to be replaced?" When a patient presents with mild symptoms in regards to an existing restoration but the standard procedures (examination and possibly radiographs) are inconclusive, do we replace or observe the restoration? Have you ever had a patient say "But it doesn't hurt" when you have told them that they have a restoration with recurrent decay? There is a simple technology to use that will help both the patient and the clinician understand the need for treatment. For me, The Canary System® is that technology.

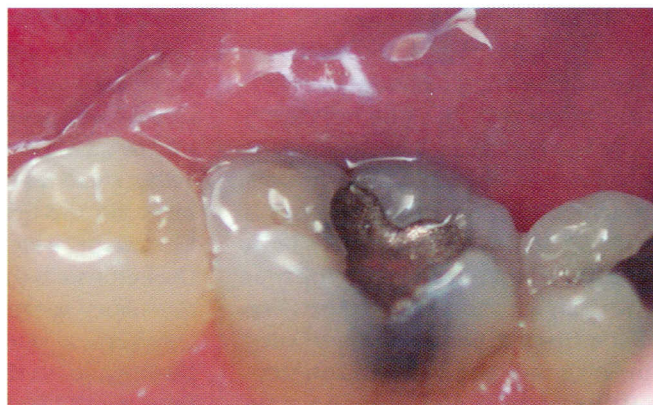
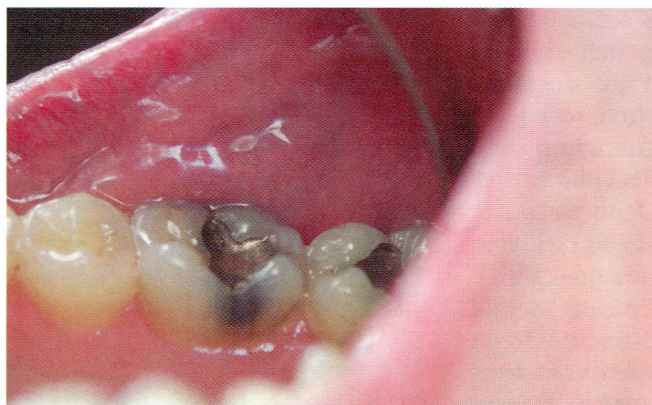
Over the past three years I have used it to help assess caries in teeth and recurrent decay along restoration margins.

The Canary System® uses energy conversion technology (PTR-LUM) to image and examine the tooth. Pulses of laser light are aimed at the tooth, and the energy is then converted into heat (Photothermal Radiometry or PTR) and light (luminescence or LUM), which are collected from the tooth between pulses. These harmless pulses of laser energy enable the clinician to examine sub-surface caries up to five mm below the surface, which are not visible to the naked eye.<sup>1, 2</sup> A recently completed clinical trial at the University of Texas comparing The Canary System® to

bitewing radiographs found that The Canary System® detected caries 92 percent of the time compared to radiographs at 67 percent of the time.<sup>3</sup>

### The Case

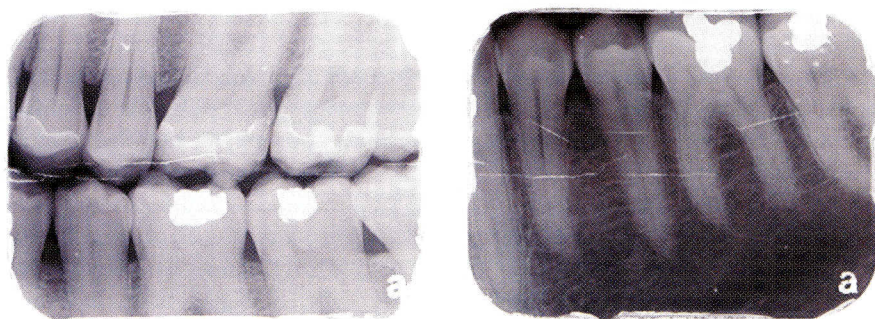
Three years ago, a 52-year-old male patient presented to our practice with low caries risk as per the Caries Management by Risk Assessment (CAMBRA) rankings. The patient complained of mild pain on chewing in the mandibular left posterior area centered on tooth 36. On visual examination there were amalgam restorations on the buccal and occlusal surfaces of tooth 36 and the occlusal surface of tooth 37 (Figure 1). The amalgams were at least 30 years



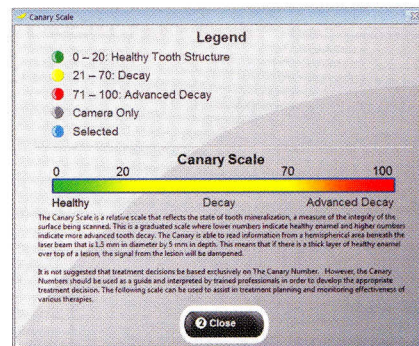
**Figure 1**

Lingual view of teeth 36 and 37 showing amalgam restorations.





**Figure 2**  
Bitewing and periapical radiograph left side with no proximal caries visible.



**Figure 3**  
The Canary Scale.

old but the margins appeared intact. Given that bitewing and periapical radiographs (Figure 2) did not reveal any indications of caries or apical pathology, we decided to scan the margins of the amalgam restorations using The Canary System® to measure the integrity of the tooth's crystal structure. The Canary System® provides a relative scale ranging from 0 – 100 indicating the level of decay (Figure 3). Numbers 0 – 20 indicate healthy teeth; numbers 21 – 70 indicate some level of early decay; and numbers 71 – 100 indicate advanced decay. Scanning with The Canary System®, we found readings ranging from 48 – 50 (Figure 4). We also decided to scan the mesial marginal ridge of tooth 37, which provided a reading of 71 (Figure 4). These findings indicated caries along the margins of these restorations. Removal of the amalgam restorations confirmed the findings (Figure 5). Decay was found, as expected. Bonded composite restorations were placed on tooth 36 and 37. Three years later, these teeth are asymptomatic with no indication of any further caries breakdown.

While technology is not a substitute for sound clinical judgement, The Canary System® can provide a valuable aid in diagnosing treatment needs. 📷

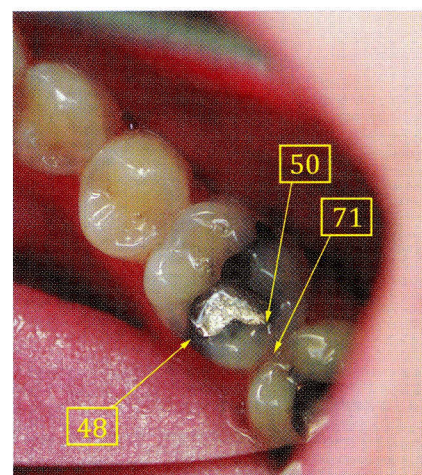
**REFERENCES**

1. Jeon, R.J., Phan, T.D.T., Wu, A., Kulkarni, G., Abrams, S.H., and Mandelis, A., "Photoacoustic and Photothermal Phenomena, July 5 – 8, 2004, J. Physique IV France, 2005; 125: 721 – 723

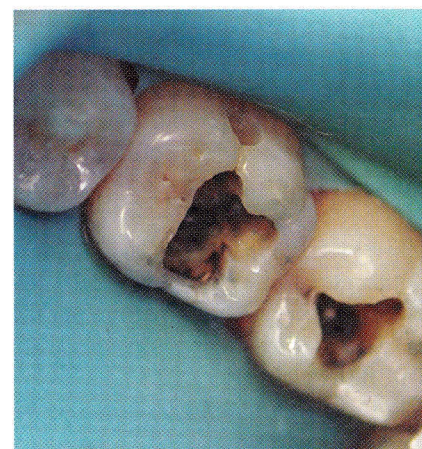2. Jeon, R.J., Matvienko, A., Mandelis, A., Abrams, S.H., Amaechi, B.T., Kulkarni, G., "Detection of Interproximal Demineralized Lesions on Human Teeth in Vitro Using Frequency-Domain Infrared Photoacoustic Radiometry and Modulated Luminescence." J. BioMed. Optics, 2007; 12(3); 034028 1 – 13

3. Uzamere, E.O., Jan, J., Bakar, W.W., Mathews, S.M., Amaechi, B. "Clinical Trial of the Canary System for Proximal Caries Detection." J Dent Res Vol # 94 (Spec Iss A): 0346, 2015 (www.iadr.org)

*Dr. Giulio Spagnuolo was born in London, Ont. He graduated from the University of Western Ontario's Faculty of Dentistry in 1984 and has been practising as a general dentist in London since then. Dr. Spagnuolo is a Fellow in the Academy of General Dentistry (1993) and was the President of the London District Dental Society in 2009/2010. Dr. Spagnuolo is not affiliated with The Canary System®.*



**Figure 4**  
Occlusal view of teeth 36 and 37 with superimposed Canary readings.



**Figure 5**  
Occlusal view after removal of amalgams showing marginal caries.